



Comparative evaluation of platelet-rich plasma + β -tricalcium phosphate and platelet-rich fibrin + β -tricalcium phosphate for healing periapical lesions, using cone beam computed tomography – an *in vivo* study

Mahendran Kavitha¹, Raju Krishnaveni², Shanmugam Jaikailash³, Muthukrishnan Sudharshana Ranjani¹, Rangarajan Hemamalini⁴, Kakade Madhura Rohit⁵

1) Department of Conservative Dentistry & Endodontics, Tamil Nadu Government Dental College & Hospital, Chennai. The Tamil Nadu Dr. M. G. R. Medical University, Chennai, Tamil Nadu, India

2) Dental Surgeon, Government Hospital, Kotagiri, Nilgiris, Tamil Nadu, India

3) Department of Dental Surgery, Government Coimbatore Medical College Hospital, Coimbatore, Tamil Nadu, India

4) Department of Conservative Dentistry & Endodontics, Dhanalakshmi Srinivasan Dental College & Hospital, Perambalur, Tamil Nadu, India

5) Department of Conservative Dentistry & Endodontics, C.S.M.S.S Dental College & Hospital. Chatrapati Sambhaji Nagar, Maharashtra, India

DOI: 10.15386/mpr-2637

Manuscript received: 04.05.2023

Received in revised form: 08.06.2023

Accepted: 10.07.2023

Address for correspondence:

Muthukrishnan Sudharshana Ranjani
msranj@gmail.com

This work is licensed under a Creative Commons Attribution-NonCommercial-NoDerivatives 4.0 International License
<https://creativecommons.org/licenses/by-nc-nd/4.0/>

Abstract

Background. Platelet concentrates are currently being researched for their potential to enhance bone formation.

Aim. The aim of this study is to quantitatively evaluate and compare bone regeneration in periapical lesions using a combination of platelet-rich plasma (PRP) + β -tricalcium phosphate (β -TCP) and platelet-rich fibrin (PRF) + β -TCP.

Methods. Ten subjects with periapical lesions measuring 10-20 mm in relation to maxillary incisors indicated for periapical surgery were selected. Pre-operative bone density values at the periapical region were measured using CBCT. Root canal treatment was completed appropriately in all cases. Under adequate local anesthesia, periapical surgery was performed. The 10 subjects were distributed into two groups of 5 subjects in each group. Group I: Periapical bone defect filled with PRP + β -TCP and Group II: Periapical bone defect filled with PRF + β -TCP. The mucoperiosteal flaps were repositioned and sutured. Bone density evaluation of the periapical region was done 6 months and 1 year after surgery using cone beam computed tomography (CBCT). The Hounsfield unit (HU) values obtained were subjected to statistical analysis by Independent samples t-test for inter-group comparison. The intra-group comparison was done by repeated measure ANOVA and Bonferroni post hoc tests.

Results. In Group I and Group II, a statistically significant difference was observed at the end of 6 months and 1 year, when compared to the pre-operative values ($P=0.000$). There was no statistically significant difference in bone density values between the PRP + β -TCP and PRF + β -TCP groups at both 6 months and 1-year post-operative observation periods.

Conclusion. PRP + β -TCP and PRF + β -TCP were equally effective in promoting bone regeneration and can be considered valuable bioactive surgical additives for enhancement of healing in periapical bone defects.

Keywords: β -tricalcium phosphate, bone regeneration, cone beam computed tomography, periapical surgery, platelet-rich plasma, platelet-rich fibrin

Introduction

The microbial infection of the dental pulp results in pulp tissue necrosis which leads to the development of the inflammatory periapical lesion. Periapical surgery is performed when the periapical lesion cannot be resolved by non-surgical treatment procedures because of the presence of persistent pathosis and in teeth with large periradicular lesions greater than 15 mm in diameter [1]. The healing after endodontic periapical surgery occurs by repair or regeneration depending on the nature of the wound, availability of progenitor cells, and biological growth factors. Current bone healing research is aimed to accelerate bone regeneration to enhance predictability as well as the volume of regenerated bone.

Various bone substitutes are tried to achieve regeneration of the bone and optimal healing. Among the synthetic graft materials, calcium phosphate ceramics like hydroxyapatite and β -TCP are widely used due to their excellent biocompatibility [2]. Earlier works of literature have suggested β -TCP as an excellent bone augmentation material with osteoconductive and osteoinductive properties [3-5]. But the drawback with β -TCP is that the time span required for the replacement of this biomaterial with bone is long [6]. This can be overcome by the addition of biological modulators like the use of bone morphogenetic proteins, growth factors, and extracellular matrix. Among the rich sources of autologous growth factors, PRP and PRF are now widely researched for their applications in various disciplines of dentistry.

Whitman developed PRP in 1997, the first generation of autologous platelet concentrate [7]. This is a rich source of growth factors and its application is thought to induce tissue repair and regeneration [8]. Marx et al. reported that PRP when added to bone grafts accelerated the rate of bone formation [9]. PRF, the second-generation platelet concentrate was introduced by Choukroun [10]. PRF is enriched with platelets and growth factors and aids in periapical tissue regeneration and healing. Previous studies have proved their potential role in promoting soft tissue and bone regeneration in periodontal defects and post-extraction sockets when used alone or in combination with various graft materials [11-13]. They are suitable as an ideal scaffold in the revascularization of immature permanent teeth with necrotic pulps [14].

In this in vivo study, PRP + β -TCP and PRF + β -TCP were used in periapical bone defects and a comparative evaluation of healing was done using cone beam computed tomography (CBCT) after a postoperative period of 6 months and one year.

Methods

Study design

Ethical clearance was obtained from the Institution's

Ethical Committee. Patients reporting to the Department of Conservative Dentistry and Endodontics were included in the study. The complete treatment procedure was explained to the patients and written informed consent was obtained from all the patients selected for the study.

Inclusion criteria

- Patients with age group 20-40 years of either gender
- Periapical lesions involving maxillary incisors of endodontic origin.
- The diameter of the bone defect of 10 -20 mm
- Patients willing for voluntary participation.
- Patients with good oral hygiene.
- Systemically healthy subjects

Exclusion criteria

- Periodontally compromised teeth with poor prognosis.
- Tooth with pathosis associated with vertical root fracture.
- Patients with bleeding disorders.
- Platelet count $<150,000/\text{mm}^3$.
- Patients showing unacceptable oral hygiene maintenance.
- Patients with the use of tobacco or tobacco-related products.
- Pregnant / Lactating patients.
- Patients with known systemic diseases.
- Patients with any known allergies.
- Patients with any known metabolic disorders.

Ten subjects who fulfilled the above-mentioned criteria were selected for the study and were divided into two groups:

- Group I : (n=5) peri apical bone defect filled with PRP + β -TCP
- Group II : (n=5) peri apical bone defect filled with PRF + β -TCP

Pre-operative evaluation of the patients

For all the patients selected for the study, medical and dental history was recorded. Intraoral examination was done to assess the nature of the presenting illness, the oral hygiene status, periodontal status, and restorability of the involved tooth. An intraoral periapical radiograph was obtained using paralleling technique with XCP film-holding instruments. Cold test and Electric pulp testing were performed to assess the vitality of the teeth. Routine blood investigations were carried out for all the patients. CBCT scan (Planmeca Helsinki, Finland) was taken (90 kV, 10 mA, FOV-50 mm) and the pre-operative bone density values were recorded in Hounsfield Units using Romexis software. HU values were obtained from the sagittal section at the mid-slice level of the involved tooth calculating an average of 10 values at various points within the lesion (Figures 1A, 2A).

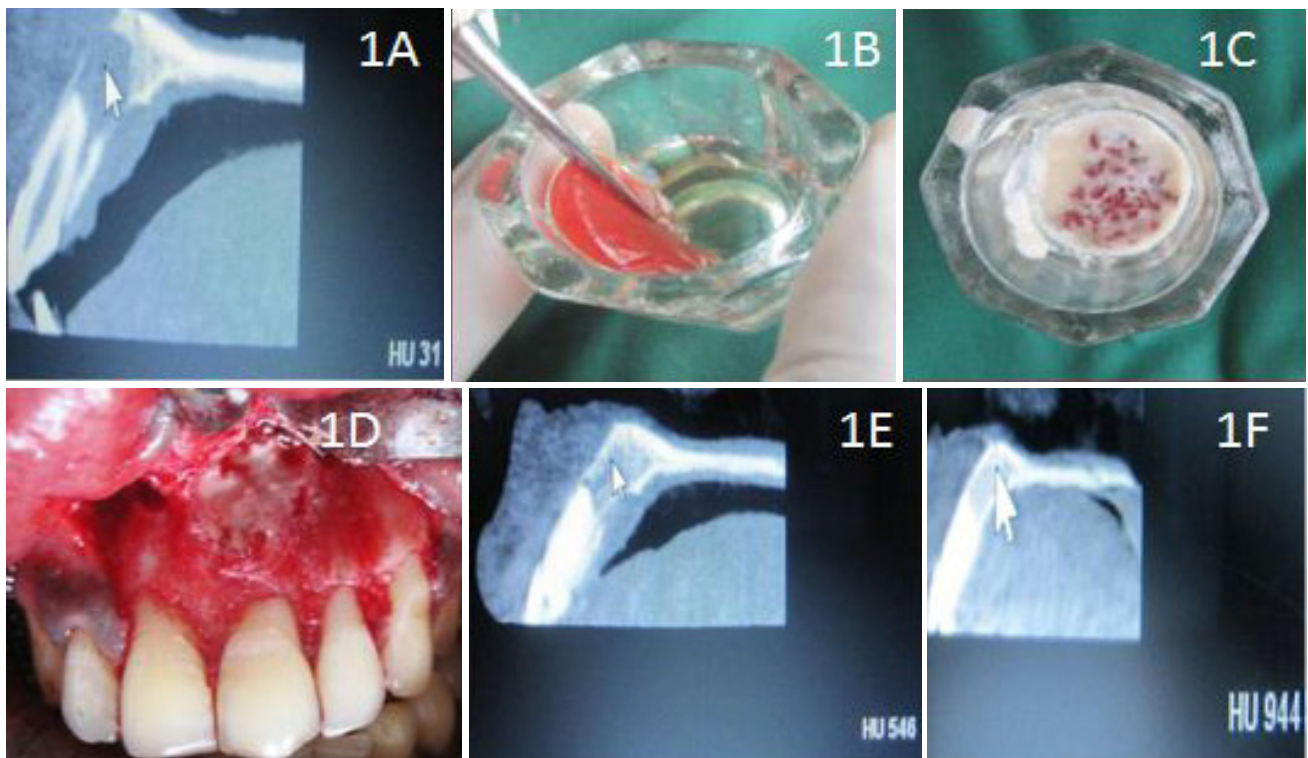


Figure 1. A. Preoperative CBCT image with HU value; B. Preparation of PRP gel; C. Mixing of PRP with β -TCP; D. Placement of PRP + β -TCP in the defect; E. 6 months post-op CBCT image with HU value; F. 1-year post-op CBCT image with HU value.

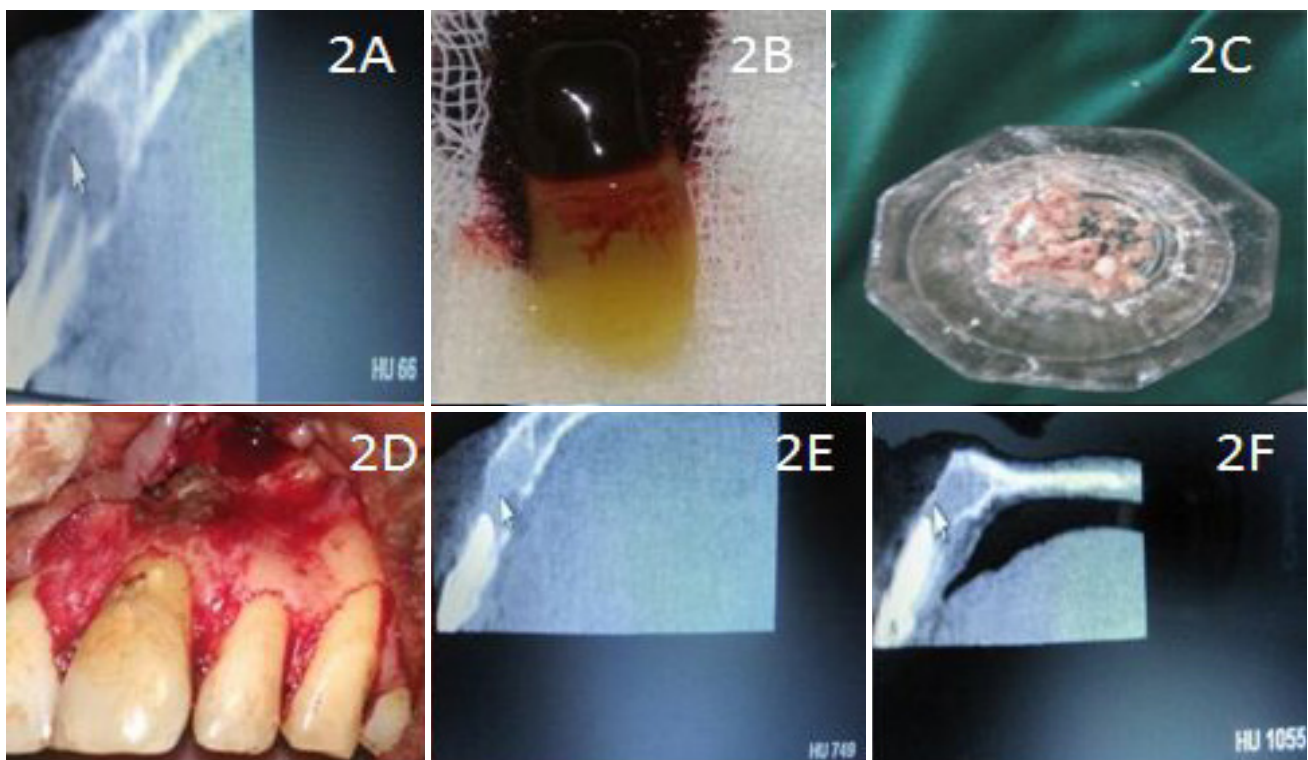


Figure 2. A. Preoperative CBCT image with HU value; B. Preparation of PRF; C. Mixing of PRF with β -TCP; D. Placement of PRF + β -TCP in the defect; E. 6 months post-op CBCT image with HU value; F. 1 year post op CBCT image with HU value.

Root canal treatment

Oral prophylaxis was done before the commencement of the treatment. Under rubber dam isolation, a straight-line access cavity was made using a high-speed airtor handpiece and sterile burs. Canals were negotiated using K-files. Working length was determined and chemo-mechanical preparation was completed using standardized technique and appropriate size K-files. Canals were irrigated using 3% sodium hypochlorite, 17% Ethylene-diamine-tetra-acetic acid, and saline. Canals were dried with paper points. Calcium hydroxide intracanal medicament (RC Cal, Prime Dental Products (P) Ltd.) was placed for 2 weeks in two consecutive appointments. Subsequently, obturation was completed using Gutta Percha and AH plus jet sealer by lateral condensation technique. The access cavity was restored with composite (Ivoclar, Vivadent).

Surgical procedure

All the surgical procedures were performed by a single operator. Extraoral antisepsis and intra-oral antisepsis were performed with 5% povidone-iodine solution and 0.2% chlorhexidine digluconate rinse respectively. The operative site was anesthetized with 2% Lignocaine HCl with adrenaline (1:80,000) using infraorbital nerve block and infiltration techniques. Crevicular incisions were made on the labial surfaces, extending to each side of the involved tooth using the Bard-Parker blade No.15. A full-thickness mucoperiosteal flap was reflected using the periosteal elevator. Care was taken to preserve interdental papillary tissue. After reflection of the flap and exposure of the osseous defect, a thorough surgical debridement was done using a curette. Osseous margins were smoothed. Debridement was followed by copious irrigation with 0.9% normal saline. The root end was resected and the retrograde filling was done with Glass Ionomer Cement (GC Fuji II, Japan).

PRP preparation

PRP was prepared in accordance with the protocol developed by Sonleitner et al [15]. 10 ml of venous blood was drawn from the patient's antecubital vein and transferred into the test tube containing acid citrate dextrose A solution as an anticoagulant and shaken gently to enhance the complete mixing of the blood with anticoagulant. The tube was then centrifuged (Remi-India) at 1200 rpm (160 g) for 20 minutes to separate the PRP and the platelet-poor plasma (PPP) from the red blood cells. The supernatant plasma was then aspirated with a micropipette and transferred to a sterile test tube without an anticoagulant. This was subjected to a second centrifugation at 2000 rpm (400 g) for 15 minutes, which allowed the precipitation of the platelets to fall onto the bottom while the surface PPP was discarded using a micropipette. The PRP was transferred to a dappen dish (Figure 1B).

PRF preparation

PRF was prepared in accordance with the protocol developed by Choukroun [10]. 10 ml of venous blood was

drawn from the patient's antecubital vein and transferred into a test tube without an anticoagulant. The tube was immediately centrifuged at 3000 rpm (400 g) for 10 minutes. A structured fibrin clot was formed in the middle of the tube, just between acellular plasma at the top and the red corpuscles at the bottom. PRF was separated from the red corpuscles base (preserving a small RBC layer) using sterile tweezers (Figure 2B) just after the removal of PPP and then transferred into a sterile dappen dish.

In group I, the defect was filled with a combination of PRP and β -TCP (Sybograf -T, Eucare Pharmaceuticals (P) Ltd.). β -TCP bone graft material was added to PRP fluid in the dappen dish (Figure 1C). The activating agent consisting of 10% calcium chloride solution and 100 μ g/ml bovine thrombin (Thermo Fisher Scientific India Pvt. Ltd.) was added at a ratio of 1:1. The mixture was then placed in the defect (Figure 1D). In group II, the defect was filled with a combination of PRF and β -TCP. Freshly prepared PRF gel was cut into small pieces and mixed with β -TCP bone graft material (Figure 2C). The mixture was then placed into the osseous defect (Figure 2D).

The mucoperiosteal flaps were repositioned and sutured using 3-0 black silk. All patients were prescribed systemic antibiotics (Amoxicillin 500 mg thrice daily, Metronidazole 400 mg twice daily), analgesics (Ibuprofen 400 mg thrice daily), and Ranitidine 150 mg thrice daily, for 5 days. Post-operative instructions were given to all the patients. Re-evaluation for any acute signs of inflammation or infection was done 24 hours post-surgically. 7 days following surgery, the sutures were removed and the surgical site was irrigated with normal saline. Patients were observed for any signs or symptoms of post-operative complications.

Post-operative follow-up

The patients were reviewed at regular intervals of one, three, six, nine, and twelve months. These follow-up visits included routine intraoral examinations and professional plaque control. Bone density evaluation of the periapical region using CBCT was done 6 months (Figures 1E, 2E) and 1 year (Figures 1F, 2F) after surgery, and the HU values were obtained following the same procedure as explained for pre-operative HU values.

The data obtained were subjected to statistical analysis. The dependent variable was the bone healing outcome. The independent variables analyzed were two different materials and at various intervals of time. Intra-group comparison between the pre-op, 6 months post-op, and 1-year post-op HU values at various intervals of time, was done for each group using One-way repeated measure ANOVA and Bonferroni post hoc tests. As the data obtained was quantitative, an inter-group comparison of HU values between Group I and Group II was done using the Independent samples test.

Results

No apparent adverse events were seen throughout the observation period. All 10 patients reported back for review as instructed.

Table I depicts the age and gender distribution of the study population among the experimental groups and there is no clinically meaningful difference in the mean age and gender distribution between group I and II.

Table I. Age and gender distribution in the experimental groups.

No. of Patients	Group I		Group II	
	Age	Gender	Age	Gender
1.	23	Female	24	Female
2.	32	Male	26	Male
3.	35	Female	31	Male
4.	30	Male	37	Male
5.	28	Female	32	Female
Mean Age	29.6		30	

Table II. Mean and standard deviation of HU values for the experimental groups during different time intervals.

Groups		Pre-Op	6 Months Post –Op	1 Year Post –Op
Group I	Mean	29	626.60	967.80
	Standard Deviation	20.905	73.928	50.860
Group II	Mean	48.60	673.80	966.60
	Standard Deviation	31.214	104.545	64.411

Table II represents the mean and standard deviation of HU values for the experimental groups during the pre-

op, 6 months, and 1 year post-op period. For inter-group comparison, mean HU values obtained for group I were compared to the mean values obtained for group II using the Independent samples t-test. It was found that there was no statistically significant difference in bone density HU values between the two groups preoperatively ($P=0.313$), at 6 months ($P=0.212$), and at 1 year ($P=0.670$) post-operative period (Table III). It shows that the mean HU values were comparable between the two groups.

Table III. Inter Group Comparison- Independent samples ‘t-test’.

Time	Sig. (P value)	95% Confidence Interval Of The Difference
Preop	0.313	[-58.342, 19.142] [-59.342, 20.142]
Post Op 6 Months	0.212	[-179.248, 84.848] [-181.845, 87.445]
Post Op 1 year	0.670	[-83.437, 85.837] [-84.236, 85.636]

On Intra Group Comparison, Group I and group II presented a significant increase in bone density HU values during 6 months and one-year post-op periods compared to their respective pre-op values. Table IV shows a significant time effect for Group I ($P<0.001$, Wilk’s lambda value=0.001, partial $\eta^2=0.999$) and for group II ($P<0.001$, Wilk’s lambda value=0.003, partial $\eta^2=0.997$). Pairwise comparison using Bonferroni Post Hoc Tests (Table V) also showed a highly significant difference between the pre-op, 6 months, and 1 year values for groups I and II ($P<0.001$).

Table IV. Intra Group Comparison – One way repeated measure ANOVA.

Groups	Effect	Wilks’ Lambda Value	F	Partial Eta Squared	Sig.(P Value)
Group I	Time	0.001	1264.844	0.999	0.000
Group II		0.003	568.312	0.997	0.000

Table V. Bonferroni post hoc tests.

Groups	(I)Time	(J) Time	Mean Difference(I-J)	Std.Error	Sig. ^b	95% Confidence Interval For Difference ^b
Group I	1	2	-597.600*	24.588	.000	[-694.987, -500.213]
		3	-938.800*	17.656	.000	[-1008.732, -868.868]
	2	1	597.600*	24.588	.000	[500.213, 500.213]
		3	-341.200*	16.323	.000	[-405.852, -276.548]
	3	1	938.800*	17.656	.000	[868.868, 1008.732]
		2	341.200*	16.323	.000	[276.548, 405.852]
Group II	1	2	-625.200*	33.448	.000	[-757.679, -492.721]
		3	-918.000*	27.120	.000	[-1025.417, -810.583]
	2	1	625.200*	33.448	.000	[492.721, 757.679]
		3	-292.800*	43.392	.008	[-464.665, -120.935]
	3	1	918.000*	27.120	.000	[810.583, 1025.417]
		2	292.800*	43.392	.008	[120.935, 464.665]

Based on estimated marginal means. * The mean difference is significant at the .05 level. ^b Adjustment for multiple comparisons: Bonferroni.

Discussion

Research was conducted on various bioactive materials to augment the healing of periapical lesions after periapical surgery. β -TCP with a Ca/P ratio of 1.5 is one such bioactive material that gets resorbed and replaced by vital bone over a period of six months [16]. PRP and PRF are biologic modulators rich in growth factors PDGF, TGF- β , IGF, EGF, VEGF, and FGF that have a potential role in bone metabolism, regulation of cell proliferation, and promoting regeneration of bone [17,18]. So, this study aimed to evaluate and compare bone healing when PRF or PRP was used in combination with the bioactive β -TCP bone graft material, to fill the bone defect after periapical debridement.

The gold standard procedure in bone healing assessment is the histological examination. But it has some drawbacks like the need for a second surgery, which interferes with healing. Conventional IOPA Radiographs allow only a two-dimensional radiographic examination. So, CBCT was opted for in this study, as it provides three-dimensional images and aids in the evaluation of periapical bone lesions and their repair after surgical endodontic treatment. Bone healing was quantitatively measured using CBCT, after a postoperative period of 6 months and 1 year. Simon et al. reported that the mineral density in the periapical region can be measured in Hounsfield units (HUs) by using CBCT [19]. Earlier studies have suggested that CBCT can be a reliable tool in assessing bone density [20-22]. The dimensional change of the periapical lesions was not performed in this study, which is one of the limitations of our study. A comparative pre-op and post-op follow-up evaluation in terms of bone density assessment along with the volumetric assessment would have provided better clinical validation [23,24].

The pre-op CBCT images revealed low bone density values. When compared to the pre-op HU values, a significant increase in bone density was observed in groups I and II after 6 months and one year. PRF and PRP degranulate within ten minutes of clot development and secrete over 90% of the growth factors from alpha granules within one hour. The growth factors immediately bind to the transmembrane receptors of osteoprogenitor cells and mesenchymal cells [25]. Because of the increased concentration of platelets, the PRP/PRF initiates a greater and faster cellular response in the bone graft than in the normal blood clot. PRP/PRF gets resorbed in approximately 7-10 days [26]. The addition of β -TCP to PRF and PRP accelerates healing by providing graft stabilization, wound sealing, hemostasis, and improved handling properties. Moreover β -TCP acts as a scaffold upon which PRP/PRF establish their effects by their growth factors and accelerate the rate and degree of bone formation. Wiltfang et al. reported 8% to 10% more bone formation when PRP was added to β -

tricalcium phosphate [27]. Kim et al. combined PRF with β -TCP and observed rapid bone formation, remodelling, and calcification in the second week than β -TCP alone in rabbits [28]. Similar synergistic effects of PRF and β -TCP were reported to enhance healing in periodontal bone defects and extraction defect healing [29,30]. In a recent study, it was reported that a composite scaffold of poly(ϵ) caprolactone, β -tricalcium phosphate (PCL-TCP), mesenchymal stem cells (MSCs) and platelet-rich plasma (PRP) boosted bone regeneration in bone defects surrounding dental implants [31].

On inter-group comparison, there was no statistically significant difference in bone density HU values between the two groups after 6 months and 1 year postoperatively. This result was different from the animal study reported by Park et al. He reported that the bone formation with the PRF + β -TCP group was greater when compared to PRP + β -TCP [32]. This difference could be attributed to the different follow-up periods and dissimilar evaluation techniques. On the other hand, in a randomized clinical trial by Comert Kilic et al., histologic and histomorphometric analyses of sinus floor augmentation were performed and reported that P-PRP plus β -TCP or PRF plus β -TCP is not superior to β -TCP alone [33].

In *in vivo* studies, age and gender have an influence on healing patterns. In this study, there is no clinically meaningful difference in the mean age and gender distribution between both groups. From the results of this study, both PRP and PRF when used in combination with β -TCP, demonstrated successful and promising results. PRP and PRF can be easily procured from the patient's own blood. β -TCP is also advantageous in being less expensive than many other commercially available bone graft materials. To our best knowledge, this is the first *in vivo* study to compare the healing of periapical lesions of endodontic origin using PRP + β -TCP and PRF + β -TCP. This study was not free of limitations. First, the sample size was limited with respect to the generalization of the findings. A bigger sample size would have given a better insight into the influence of age and gender on the healing outcome. Secondly, dimensional change of the periapical lesions was not performed in this study. Future clinical trials shall be conducted with a larger sample size. In addition to bone density assessment, volumetric parameters could be assessed to further validate the results of this study.

Conclusion

Within the limitations of the present study, it can be concluded that:

- Platelet aggregates PRP, PRF, and β -TCP bone graft material were well tolerated by the periapical tissues.
- CBCT evidence of an increase in bone density was observed in relation to both groups. The difference

at the end of 6 months and 1 year, when compared to the pre-operative values was statistically significant.

- There was no statistically significant difference in bone density values between the PRP + β -TCP and PRF + β -TCP groups at both 6 months and 1-year post-operative observation periods.

Thus, the synergistic effect of PRP/PRF with β -TCP can be utilized as an alternative to bone grafts in extensive periapical lesions in order to enhance bone regeneration.

References

1. Suneelkumar C, Datta K, Srinivasan MR, Kumar ST. Biphasic calcium phosphate in periapical surgery. *J Conserv Dent*. 2008;11:92-96.
2. Szabó G, Huys L, Coulthard P, Maiorana C, Garagiola U, Barabás J, et al. A prospective multicenter randomized clinical trial of autogenous bone versus beta-tricalcium phosphate graft alone for bilateral sinus elevation: histologic and histomorphometric evaluation. *Int J Oral Maxillofac Implants*. 2005;20:371-381.
3. Guillaume B. Filling bone defects with β -TCP in maxillofacial surgery: A review. *Morphologie*. 2017;101:113-119.
4. Lu H, Zhou Y, Ma Y, Xiao L, Ji W, Zhang Y, et al. Current Application of Beta-Tricalcium Phosphate in Bone Repair and Its Mechanism to Regulate Osteogenesis. *Front Mater*. 2021;8:698915.
5. Bohner M, Santoni BLG, Döbelin N. β -tricalcium phosphate for bone substitution: Synthesis and properties. *Acta Biomater*. 2020;113:23-41.
6. Choo T, Marino V, Bartold PM. Effect of PDGF-BB and beta-tricalcium phosphate (β -TCP) on bone formation around dental implants: a pilot study in sheep. *Clin Oral Implants Res*. 2013;24:158-166.
7. Whitman DH, Berry RL, Green DM. Platelet gel: an autologous alternative to fibrin glue with applications in oral and maxillofacial surgery. *J Oral Maxillofac Surg*. 1997;55:1294-1299.
8. Tözüm TF, Demiralp B. Platelet-rich plasma: a promising innovation in dentistry. *J Can Dent Assoc*. 2003;69:664.
9. Marx RE, Carlson ER, Eichstaedt RM, Schimmele SR, Strauss JE, Georgeff KR. Platelet-rich plasma: Growth factor enhancement for bone grafts. *Oral Surg Oral Med Oral Pathol Oral Radiol Endod*. 1998;85:638-646.
10. Dohan DM, Choukroun J, Diss A, Dohan SL, Dohan AJ, Mouhyi J, et al. Platelet-rich fibrin (PRF): a second-generation platelet concentrate. Part I: technological concepts and evolution. *Oral Surg Oral Med Oral Pathol Oral Radiol Endod*. 2006;101:e37-e44.
11. Mohan SP, Jaishangar N, Devy S, Narayanan A, Cherian D, Madhavan SS. Platelet-Rich Plasma and Platelet-Rich Fibrin in Periodontal Regeneration: A Review. *J Pharm Bioallied Sci*. 2019;11(Suppl 2):S126-S130.
12. Al-Maawi S, Becker K, Schwarz F, Sader R, Ghanaati S. Efficacy of platelet-rich fibrin in promoting the healing of extraction sockets: a systematic review. *Int J Implant Dent*. 2021;7:117.
13. Saini N, Sikri P, Gupta H. Evaluation of the relative efficacy of autologous platelet-rich plasma in combination with β -tricalcium phosphate alloplast versus an alloplast alone in the treatment of human periodontal infrabony defects: a clinical and radiological study. *Indian J Dent Res*. 2011;22:107-115.
14. Panda S, Mishra L, Arbildo-Vega HI, Lapinska B, Lukomska-Szymanska M, Khijmatgar S, et al. Effectiveness of Autologous Platelet Concentrates in Management of Young Immature Necrotic Permanent Teeth-A Systematic Review and Meta-Analysis. *Cells*. 2020;9:2241.
15. Sonleitner D, Huemer P, Sullivan DY. A simplified technique for producing platelet-rich plasma and platelet concentrate for intraoral bone grafting techniques: a technical note. *Int J oral Maxillofac Implants*. 2000;15:879-882.
16. Hou X, Zhang L, Zhou Z, Luo X, Wang T, Zhao X, et al. Calcium Phosphate-Based Biomaterials for Bone Repair. *J Funct Biomater*. 2022;13:187.
17. Gassling VL, Açil Y, Springer IN, Hubert N, Wiltfang J. Platelet-rich plasma and platelet-rich fibrin in human cell culture. *Oral Surg Oral Med Oral Pathol Oral Radiol Endod*. 2009;108:48-55.
18. Pavlovic V, Ciric M, Jovanovic V, Trandafilovic M, Stojanovic P. Platelet-rich fibrin: Basics of biological actions and protocol modifications. *Open Med (Wars)*. 2021;16:446-454.
19. Simon JH, Enciso R, Malfaz JM, Roges R, Bailey-Perry M, Patel A. Differential diagnosis of large periapical lesions using cone-beam computed tomography measurements and biopsy. *J Endod*. 2006;32:833-837.
20. Fuster-Torres MÁ, Peñarrocha-Diago M, Peñarrocha-Oltra D, Peñarrocha-Diago M. Relationships between bone density values from cone beam computed tomography, maximum insertion torque, and resonance frequency analysis at implant placement: a pilot study. *Int J Oral Maxillofac Implants*. 2011;26:1051-1056.
21. González-García R, Monje F. The reliability of cone-beam computed tomography to assess bone density at dental implant recipient sites: a histomorphometric analysis by micro-CT. *Clin Oral Implants Res*. 2013;24:871-879.
22. Kamburoğlu K, Kiliç C, Ozen T, Horasan S. Accuracy of chemically created periapical lesion measurements using limited cone beam computed tomography. *Dentomaxillofac Radiol*. 2010;39:95-99.
23. Pauwels R, Jacobs R, Singer SR, Mupparapu M. CBCT-based bone quality assessment: are Hounsfield units applicable? *Dentomaxillofac Radiol*. 2015;44:20140238.
24. Ramis-Alario A, Tarazona-Álvarez B, Peñarrocha-Diago M, Soto-Peñaloza D, Peñarrocha-Diago M, Peñarrocha-Oltra D. The study of bone healing after endodontic microsurgery using cone beam computed tomography: A retrospective cohort study. *J Clin Exp Dent*. 2022;14:e652-e660.
25. Dohan Ehrenfest DM, de Peppo GM, Doglioli P, Sammartino G. Slow release of growth factors and thrombospondin-1 in Choukroun's platelet-rich fibrin (PRF): a gold standard to achieve for all surgical platelet concentrates technologies.

- Growth Factors. 2009;27:63-69.
26. Baeyens W, Glineur R, Evrard L. The use of platelet concentrates: platelet-rich plasma (PRP) and platelet-rich fibrin (PRF) in bone reconstruction prior to dental implant surgery. *Rev Med Brux*. 2010;31:521-527.
27. Wiltfang J, Schlegel KA, Schultze-Mosgau S, Nkenke E, Zimmermann R, Kessler P. Sinus floor augmentation with beta-tricalciumphosphate (beta-TCP): does platelet-rich plasma promote its osseous integration and degradation? *Clin Oral Implants Res*. 2003;14:213-218.
28. Kim BJ, Kwon TK, Baek HS, Hwang DS, Kim CH, Chung IK, et al. A comparative study of the effectiveness of sinus bone grafting with recombinant human bone morphogenetic protein 2-coated tricalcium phosphate and platelet-rich fibrin-mixed tricalcium phosphate in rabbits. *Oral Surg Oral Med Oral Pathol Oral Radiol* 2012;113:583-592.
29. Pavani MP, Reddy KRKM, Reddy BH, Biraggari SK, Babu CHC, Chavan V. Evaluation of platelet-rich fibrin and tricalcium phosphate bone graft in bone fill of intrabony defects using cone-beam computed tomography: A randomized clinical trial. *J Indian Soc Periodontol*. 2021;25:138-143.
30. Jouliq WMA, Hassaneen AM, Abd El-Ghaffar AA. Evaluation Of Effect Of Beta-Tricalcium Phosphate With Platelets Rich Fibrin On Alveolar Ridge Post Extraction. *Journal of Pharmaceutical Negative Results*. 2023;209–215. Available from: <https://www.pnrjournal.com/index.php/home/article/view/6433>
31. Almansoori AA, Kwon OJ, Nam JH, Seo YK, Song HR, Lee JH. Mesenchymal stem cells and platelet-rich plasma-impregnated polycaprolactone- β tricalcium phosphate bioscaffold enhanced bone regeneration around dental implants. *Int J Implant Dent*. 2021;7:35.
32. Park JK, Joo HJ, Lee ES, Jang HS, Lim JS, Kwon JJ. The effect of PRF and PRP for new bone formation of beta-TCP in skull of white rabbit. *J Korean Assoc Maxillofac Plast Reconstr Surg*. 2011;33:19-25.
33. Cömert Kılıç S, Güngörmüş M, Parlak SN. Histologic and histomorphometric assessment of sinus-floor augmentation with beta-tricalcium phosphate alone or in combination with pure-platelet-rich plasma or platelet-rich fibrin: A randomized clinical trial. *Clin Implant Dent Relat Res*. 2017;19:959–967.